

Changing grey–white back to red–white

Author_Jost P. Prestin, Germany

Fig. 1 Old PFM crowns *in situ* with surrounding grey-coloured gingiva.

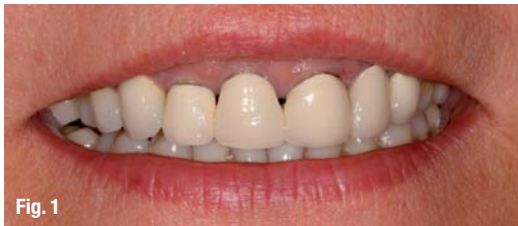

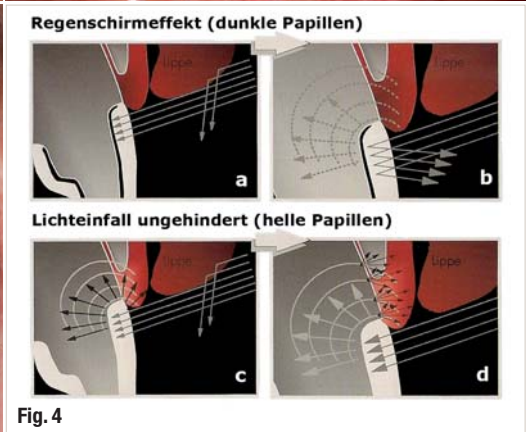
Fig. 2 Old PFM crowns, slightly exposed tooth necks of teeth 12–22 and an open margin on the crown on tooth 22.

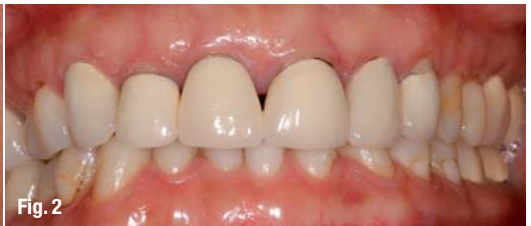
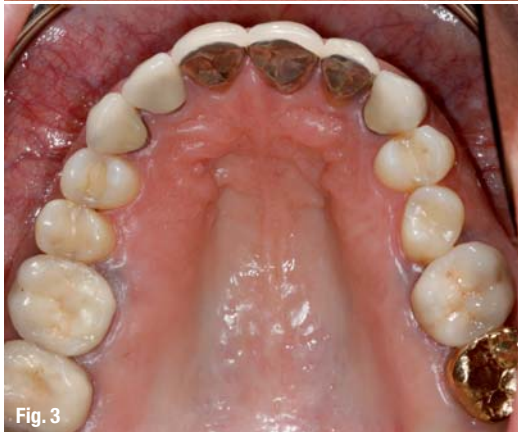
Fig. 3 View of the grey-coloured occlusal soft tissue around the anterior PFM crowns and around the PFM molars.

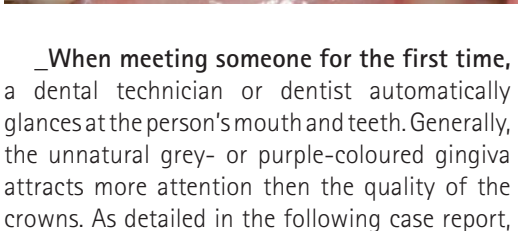


Figs. 4a–d Schematic diagram of the incidence of light. The cross-section of a tooth with a PFM crown shows that the light passes through the ceramic and is blocked by the more opaque surface of the metal coping and scattered back into the ceramic (a & b). The cross-section of a natural tooth shows that the light passes into the tooth and the mineral tooth structure scatters it in all directions (c & d). Owing to the thin alveolar bone and the thin soft tissue,



the entire area around the tooth is lit up from the inside.¹

Fig. 5 Occlusal view of the preparation with packed retraction cords.



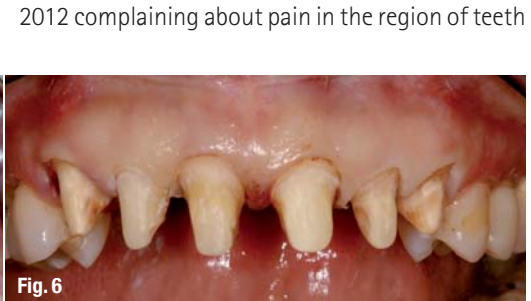_When meeting someone for the first time, a dental technician or dentist automatically glances at the person's mouth and teeth. Generally, the unnatural grey- or purple-colored gingiva attracts more attention than the quality of the crowns. As detailed in the following case report, anterior porcelain-fused-to-metal (PFM) crowns

or bridges are the main reason for this unsightly gingiva.

_Case report

A female patient came to our office in February 2012 complaining about pain in the region of teeth

Fig. 6 The preparation with the same stump shade on all stumps.



Figs. 7 & 8 Provisional *in situ* with cleared papillary areas.

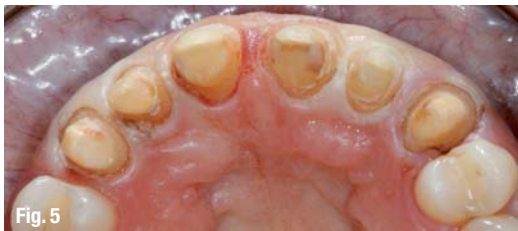

Fig. 9 The impression, taken with Aquasil Ultra.

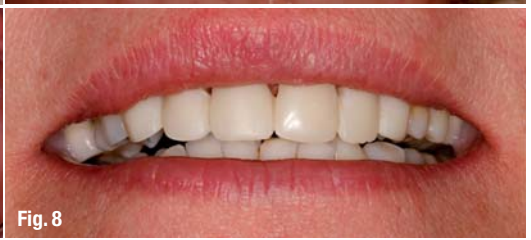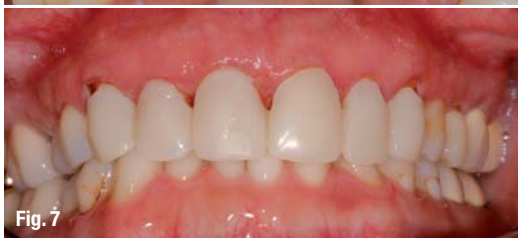Fig. 10 Close-up image of the control model.

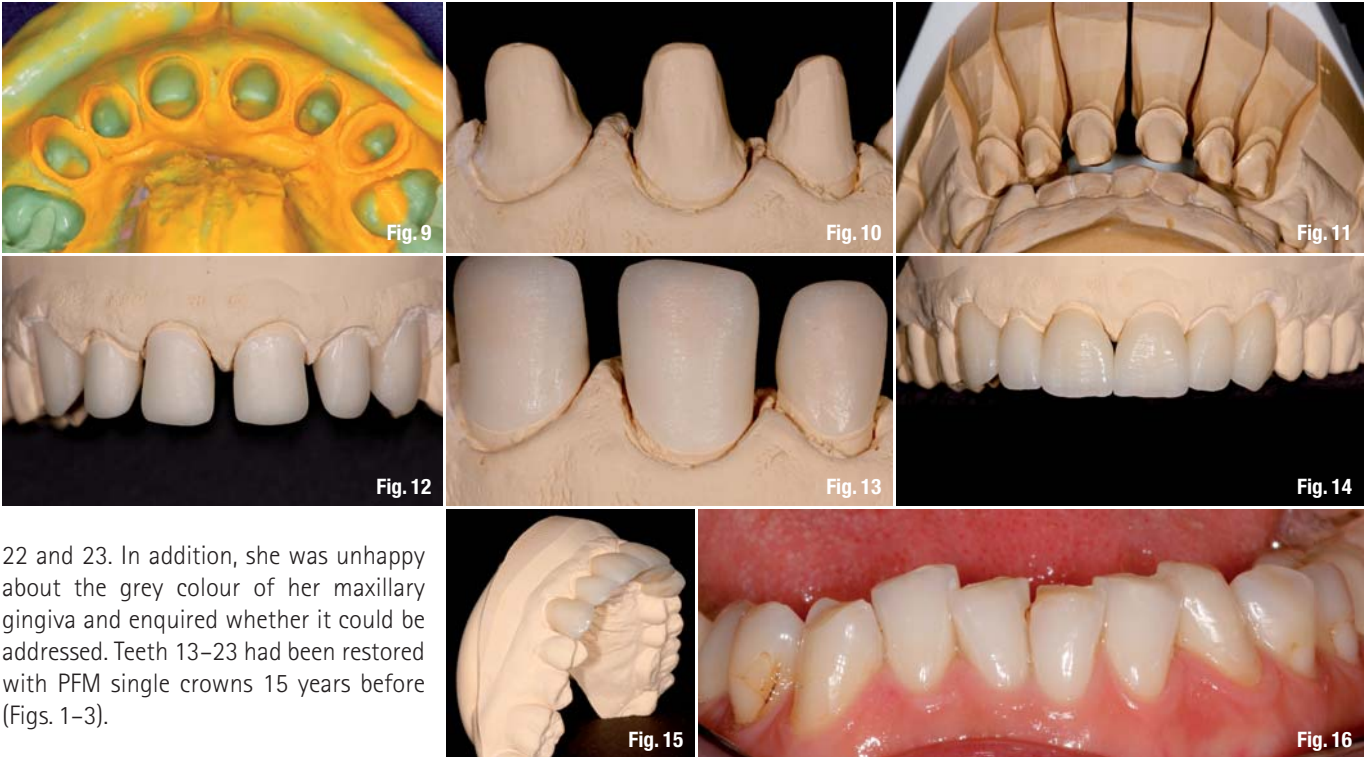
Fig. 11 Occlusal checking on the model to ensure adequate space for the crowns.

Fig. 12 The finished IPS e.max copings on the control model.

Fig. 13 Close-up image of the coping margins.

Figs. 14 & 15 Ready for the try-in.





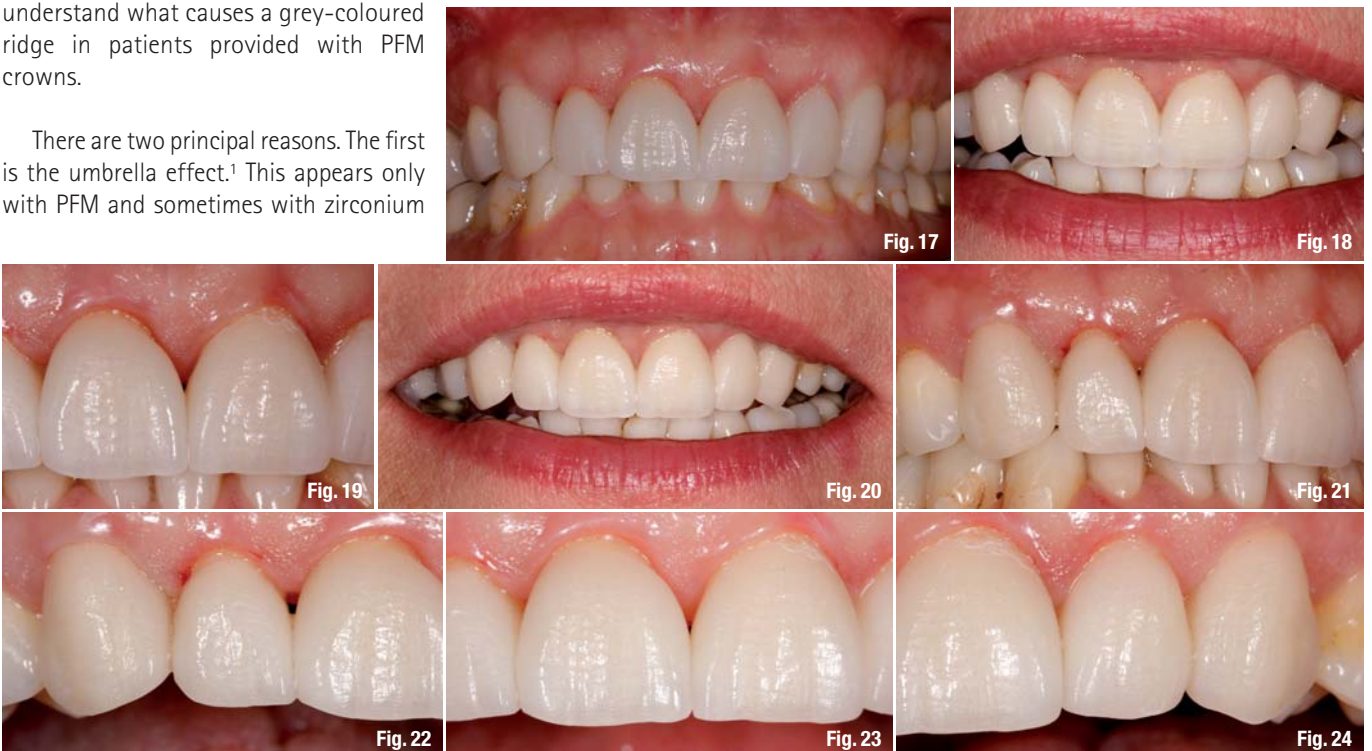
22 and 23. In addition, she was unhappy about the grey colour of her maxillary gingiva and enquired whether it could be addressed. Teeth 13–23 had been restored with PFM single crowns 15 years before (Figs. 1–3).

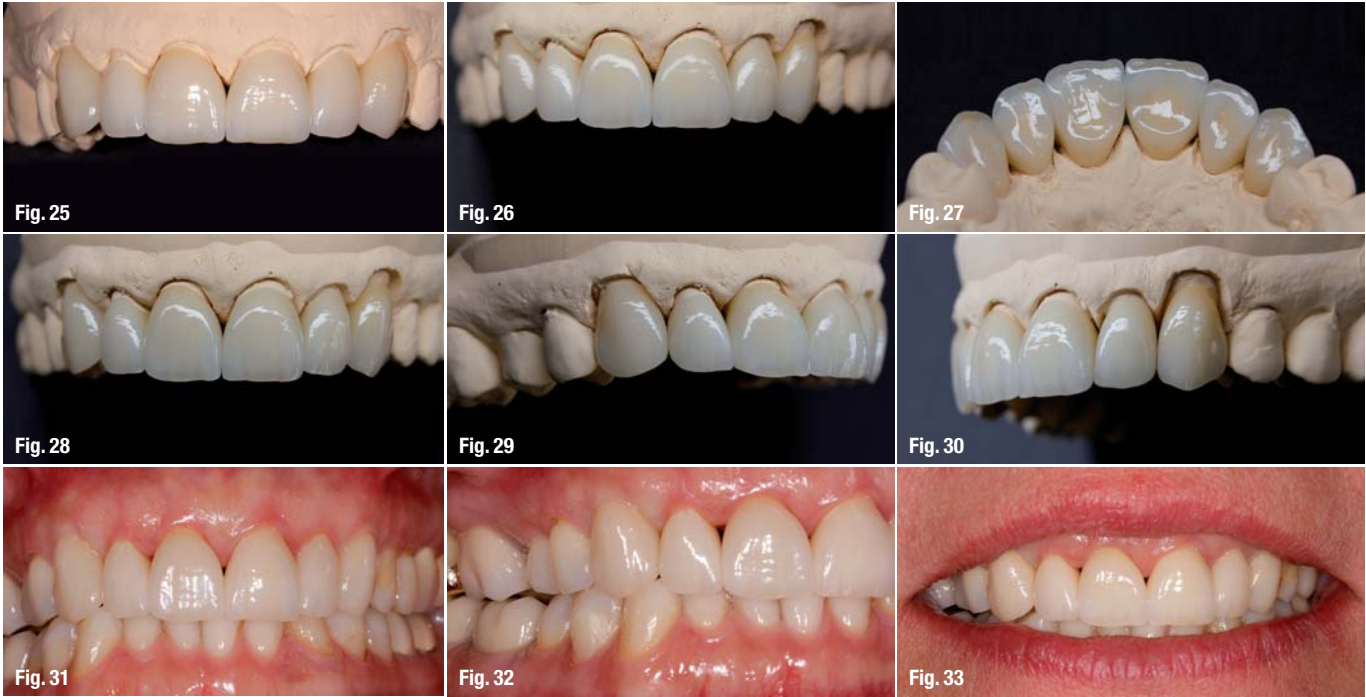After a detailed discussion of the state of the art in anterior aesthetics, we decided to renew all six PFM crowns and replace them with IPS e.max crowns (Ivoclar Vivadent). For all anterior cases, IPS e.max is our first choice of material. Not even all ceramic is all ceramic. Zirconium has nearly the same light transmission as PFM—almost nothing. Of course development goes on, and the first translucent zirconia products have been made available. It is first necessary to understand what causes a grey-coloured ridge in patients provided with PFM crowns.

There are two principal reasons. The first is the umbrella effect.¹ This appears only with PFM and sometimes with zirconium

crowns. The opaque copings block the light (Figs. 4a & b) so the root is not able to transmit the light and brighten up the papilla from the inside. Lithium disilicate glass-ceramic (except for the MO and HO ingots) is able to mimic the natural tooth. Owing to the mineral (crystalline) structure of the tooth substance and the natural light transmission of the IPS e.max restoration, the light is scattered in all

the mandibular anterior teeth for the ceramic build-up. **Figs. 17–19** IPS e.max crowns *in situ* at the try-in. **Fig. 20** Controlling the shade, including the lips. **Figs. 21–24** Controlling the approximal areas.





Figs. 25–30_An overview of the finished crowns on the control model.

Figs. 31–33_Close-up image of the papillae directly after seating of the new crowns.

directions inside the tooth, lighting up the gingiva from the inside (Figs. 4c & d). The second reason for grey gingiva underneath PFM crowns is metal oxides diffusing into the soft tissue. The possibility of dark gingiva is increased by crowns with a higher ignoble metal content.

Treatment plan

After preparing all the necessary paperwork and discussing the treatment plan again, we began removing the old crowns and finished the supragingival preparation in the middle of April. The stump shade of all six teeth was the same, allowing us to press the copings all at once in the same shade (IPS e.max Press LT A2; Figs. 5 & 6). The provisional was directly prepared in the office. It is important to leave enough space for the papillae so that they are not pushed away (Figs. 7 & 8).

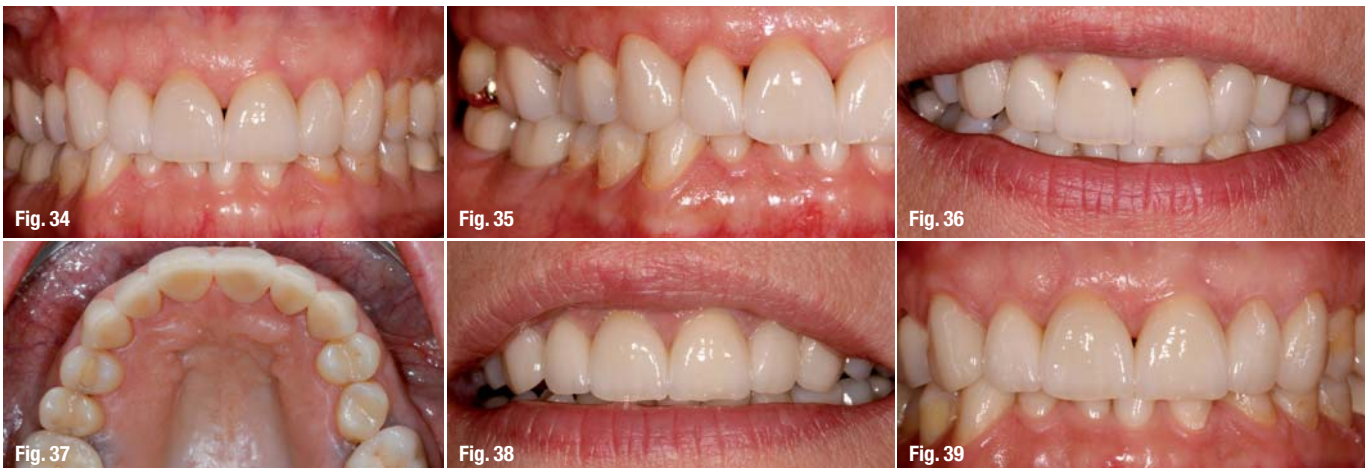
After taking the impressions using Aquasil Ultra (DENTSPLY; Fig. 9), the model work was performed (Figs. 10 & 11) and the IPS e.max copings were prepared (Fig. 12). For the pressing process, we used Vario Press 300.e (Zubler). The extremely short pressing time results in a very thin reaction layer. There is therefore no need to etch the item in hydrofluoric acid. The advantage is the perfect fit achieved because the thin margins of the copings are not rounded by etching (Fig. 13).

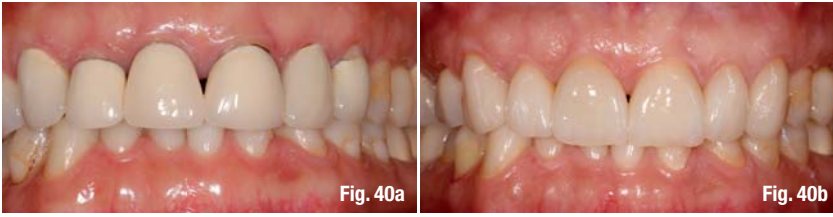
Afterwards, we applied layers of IPS e.max Ceram (Ivoclar Vivadent). The layering technique is not part of this article (Figs. 14 & 15). The shade and appearance of the tooth texture were copied from the mandibular anterior teeth (Fig. 16). For the first try-in, the crowns were in their final form and size (Figs. 17–19). The patient was more than satisfied with the result so far. We did not have to

Figs. 34–37_Final check-up one week after seating.

Fig. 38_The situation five months after seating.

Fig. 39_A small black triangle appeared between the central incisors when the saliva was blown away.





change anything. Even the colour was a perfect match (Fig. 20).

Sufficient space was left in the approximal areas to allow the papillae to regenerate (Figs. 21–23). We dislike long areas of contact that make the teeth appear square. On the maxillary left side, the papillae were almost perfect at the try-in (Fig. 24).

After that, we adjusted the surface texture and performed the glaze firing using Glaze Paste FLUO (Ivoclar Vivadent). Finally, the crowns were polished by hand with a diamond paste to obtain the highest plaque resistance possible. For the finishing, photographs are a great help. Today, capturing photographs of the teeth should be common practice

Owing to the extraordinary translucency of the IPS e.max crowns, the roots receive the same amount of light that would pass through a natural tooth (Figs. 43a & b). The soft tissue is then lit up naturally and the grey gingiva is completely gone. Also, it is interesting how well the papillae are able to regenerate (Figs. 44a & b). It may even appear that the gingival margin on PFM crowns is moving by itself to escape the metal-ion infiltration. The appearance of the papillae was improved after the all-ceramic crowns had been seated (Figs. 45a & b).

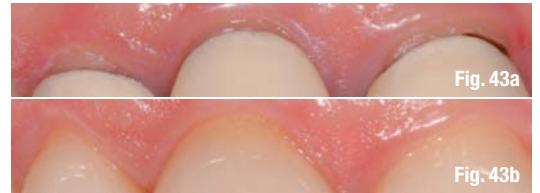
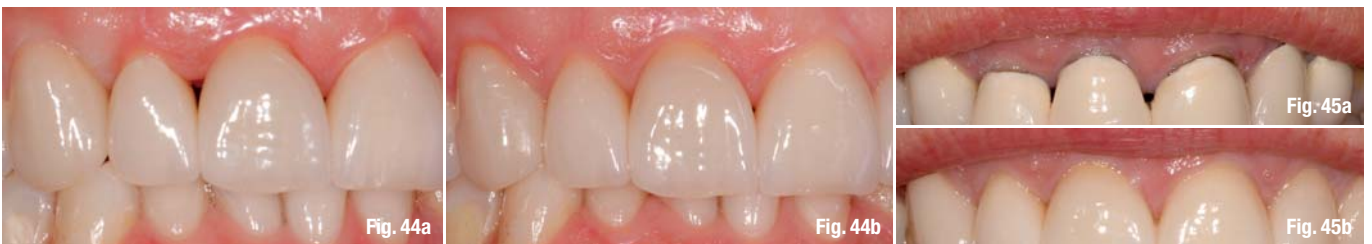
Fig. 40a & b Close-up image pre- and post-treatment.
Fig. 41 The patient with the old PFM crowns before the treatment.
Fig. 42 The patient after restoration seating.



because, especially for a case like this, no patient has the time to sit in the laboratory for hours (Figs. 25–30).

About three weeks after preparation, the crowns were seated with Syntac and Tetric Flow in shade A2 (both Ivoclar Vivadent). Little black triangles were still visible between teeth 11 and 12, and 11 and 21 (Figs. 31–33). One week later, we performed the final fit (Figs. 34–37), and we rechecked the situation five months later (in October). The patient showed a grey-free smile with perfectly formed papillae in all approximal areas (Fig. 38). At a recent follow-up, a small black triangle appeared between the central incisors when the saliva was blown away (Fig. 39).

_Final result

Six months after the start of treatment, our patient was more than satisfied with the final result (Figs. 40–42). Her request for a healthy-looking gingiva and natural-looking crowns had been fulfilled. It is almost impossible to detect artificial dentition in her new smile, even for a dentist or dental technician.

Finally, it could be said that because of the drawbacks of PFM and even zirconia we should consider using true all-ceramic crowns for such cases.

_Reference

1 P. Magne & U. Belsler, Adhäsiv befestigte Keramikrestaurationen (Berlin: Quintessenz, 2002).

cosmetic
dentistry

_contact

Jost P. Prestin, MDT
André di Mauro, DDS

Die Zahnärzte am alten Park
Hegastraße 3
78315 Radolfzell
Germany

prestin@dzaap.de
www.dzaap.de
www.jostprestin.com

Figs. 43a & b Close-up image of the gingival margin, showing the dark tooth necks due to blocked light (a), and the correct shade and translucency of the restorations (b). This result would not have been possible with zirconia crowns, for which subgingival preparation would have been required (no bleaching was involved).
Figs. 44a & b Regeneration of the approximal papillae immediately (a) and five months after seating of the new restorations (b).
Figs. 45a & b Gingiva before treatment (a) and five months after restoration (b).